



AMERICAN SOCIETY OF EMERGENCY RADIOLOGY- CASE OF THE DAY



A CURIOUS CASE OF VERTIGO

CASE REPORT PART I : THE DILEMMA

AUTHORS: AARTHI ABIRAMI¹, SRAVAN KUMAR MARUPAKA¹, RESHMA SULTANA SHAIK²

1. DEPARTMENT OF RADIODIAGNOSIS

2. DEPARTMENT OF NEUROLOGY, DECCAN COLLEGE OF MEDICAL SCIENCES, HYDERABAD

HISTORY OF PRESENTING ILLNESS

- A 59 year old man presented with the chief complaints of :
 - Vertigo and headache 2 days prior to the admission
 - Nil comorbidities

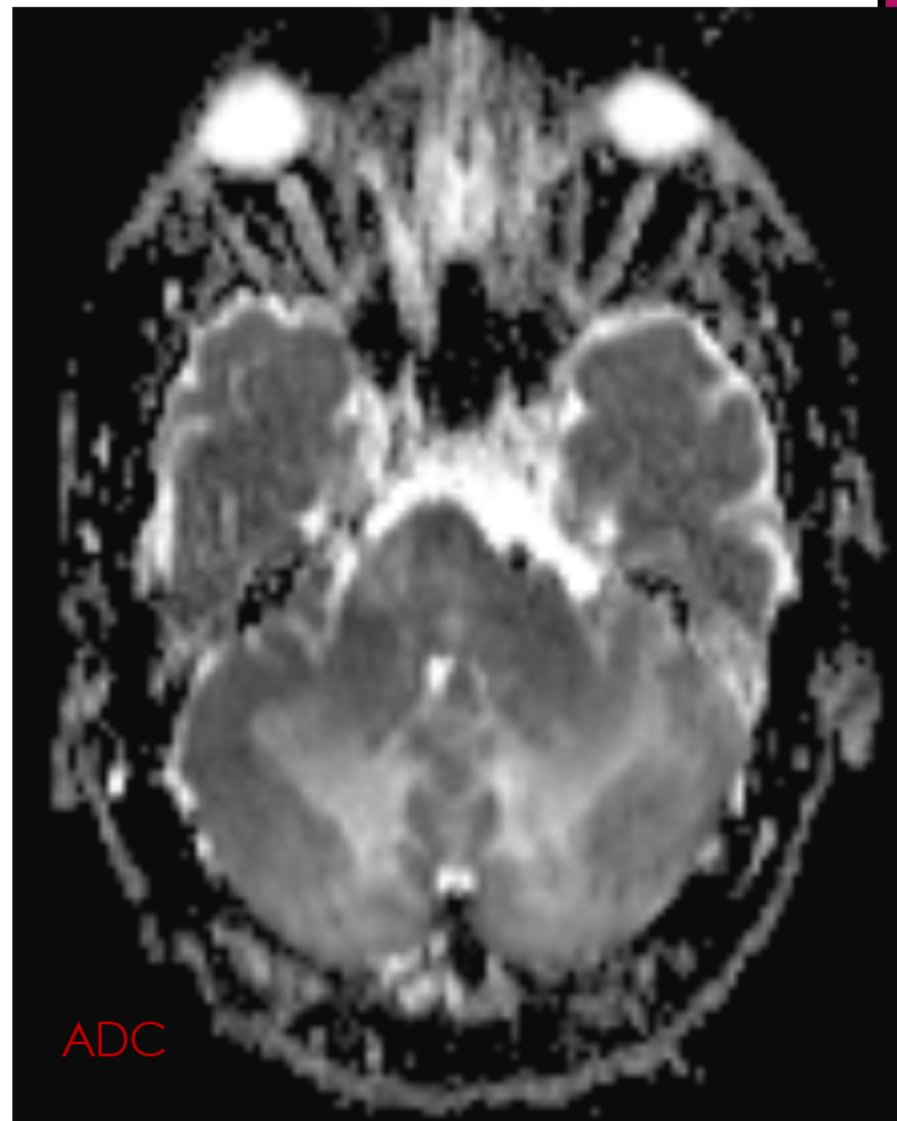
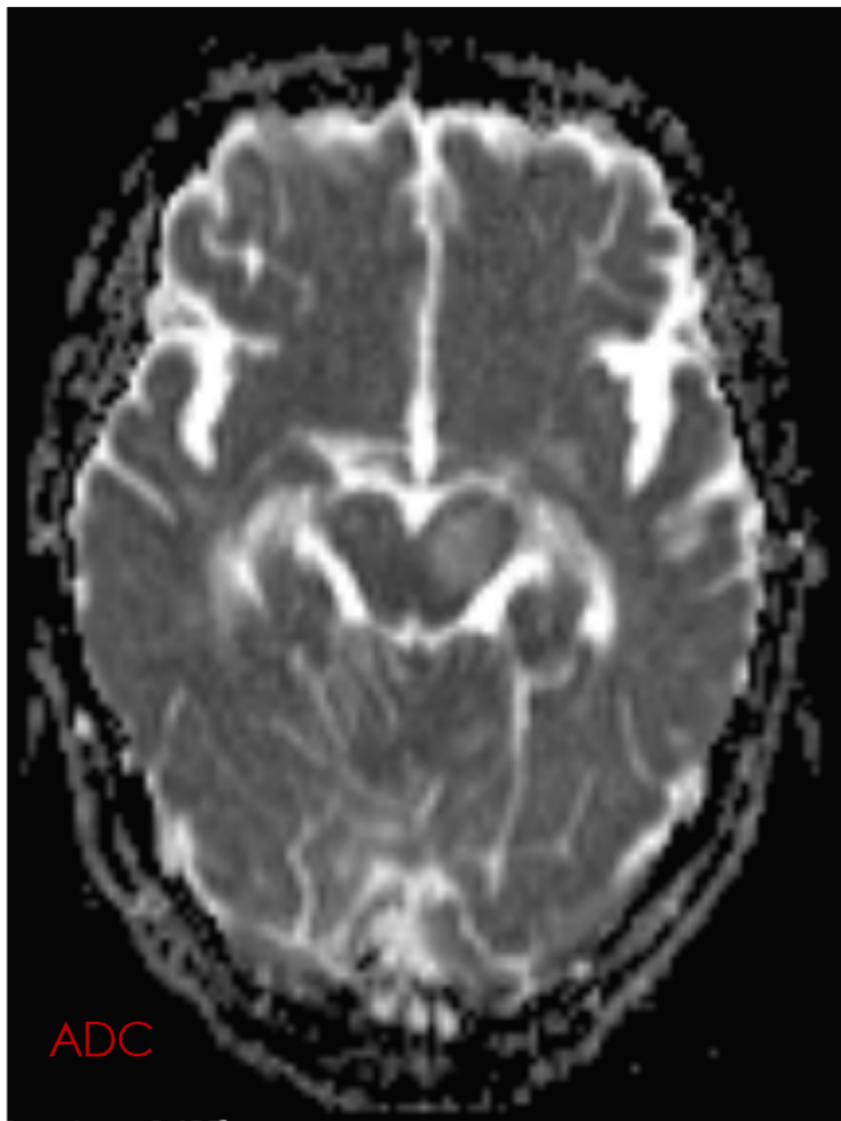


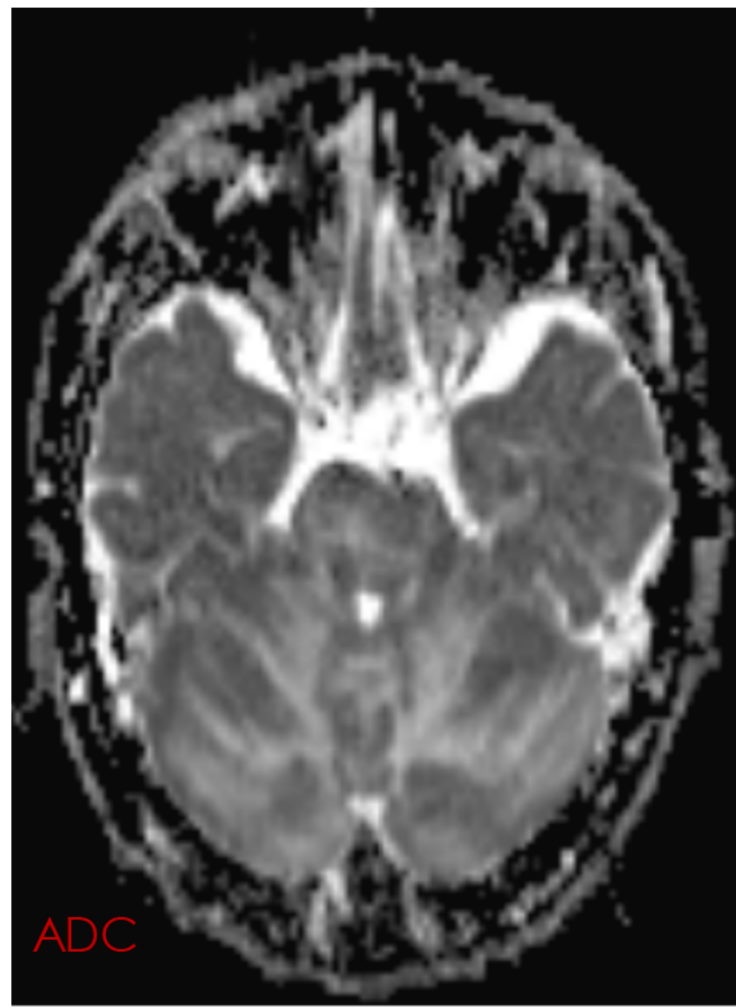
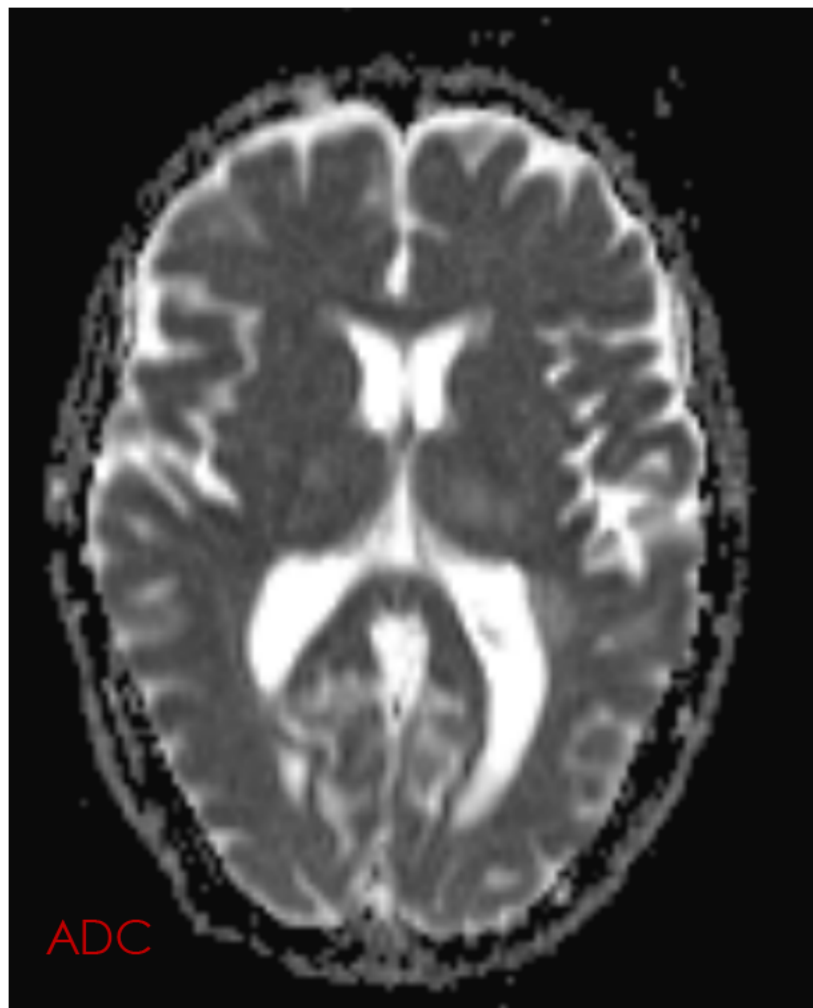
ON EXAMINATION:

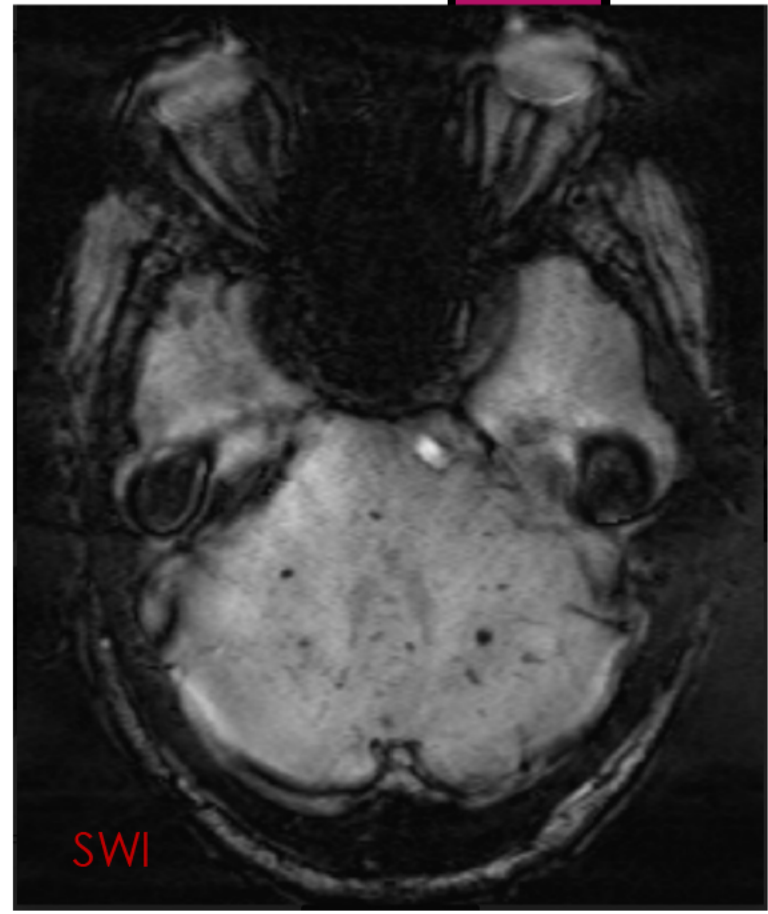
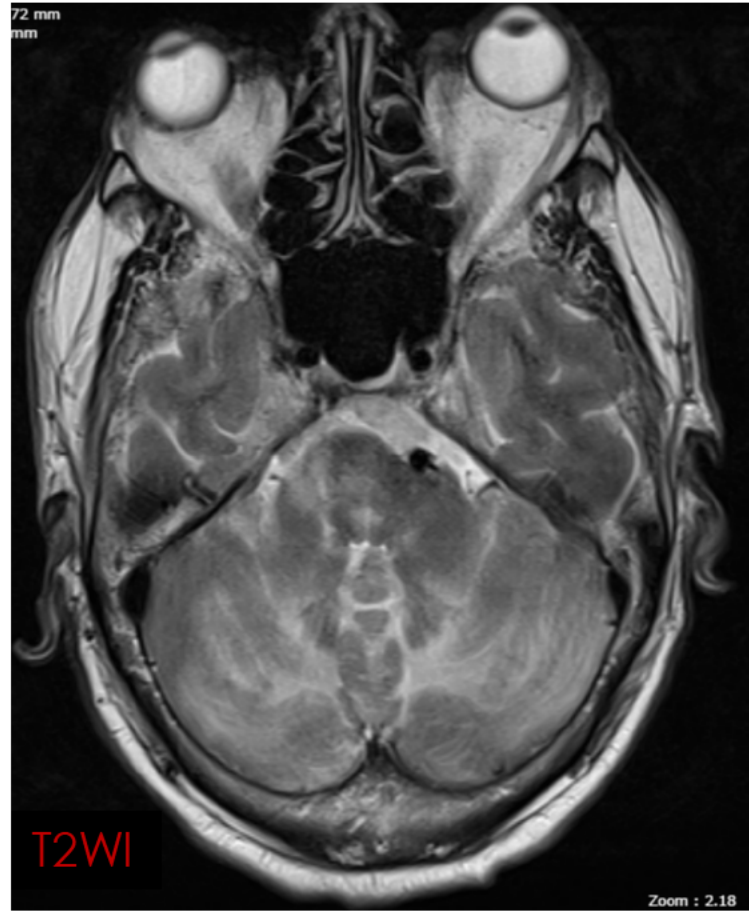
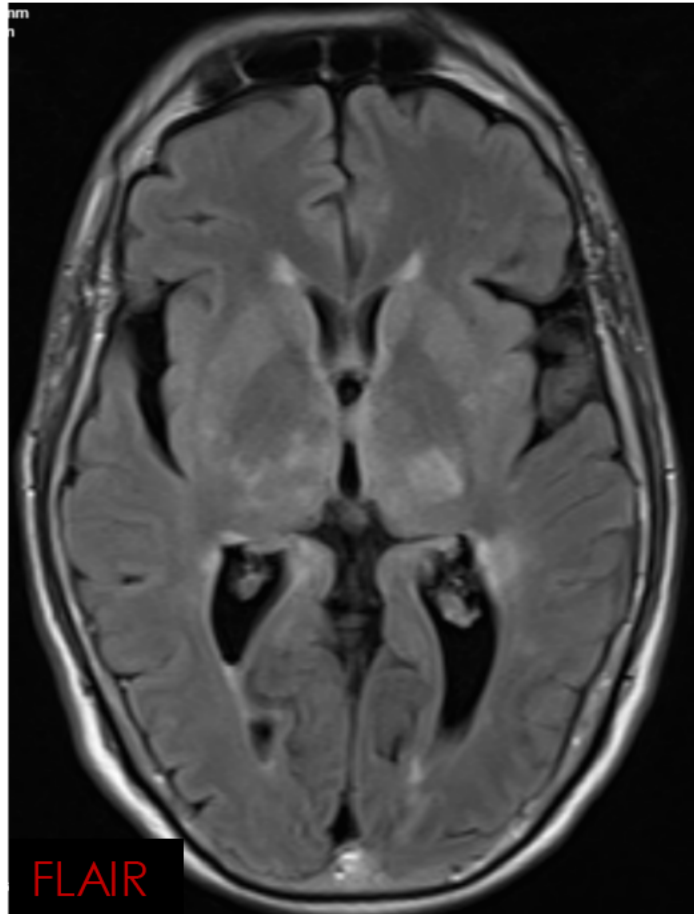
- Patient was conscious, alert and oriented
- BP at presentation was 220/120 mm Hg
- CNS examination showed cerebellar ataxia
- Other cerebellar signs- Negative
- No other lateralising features and signs of meningeal irritation


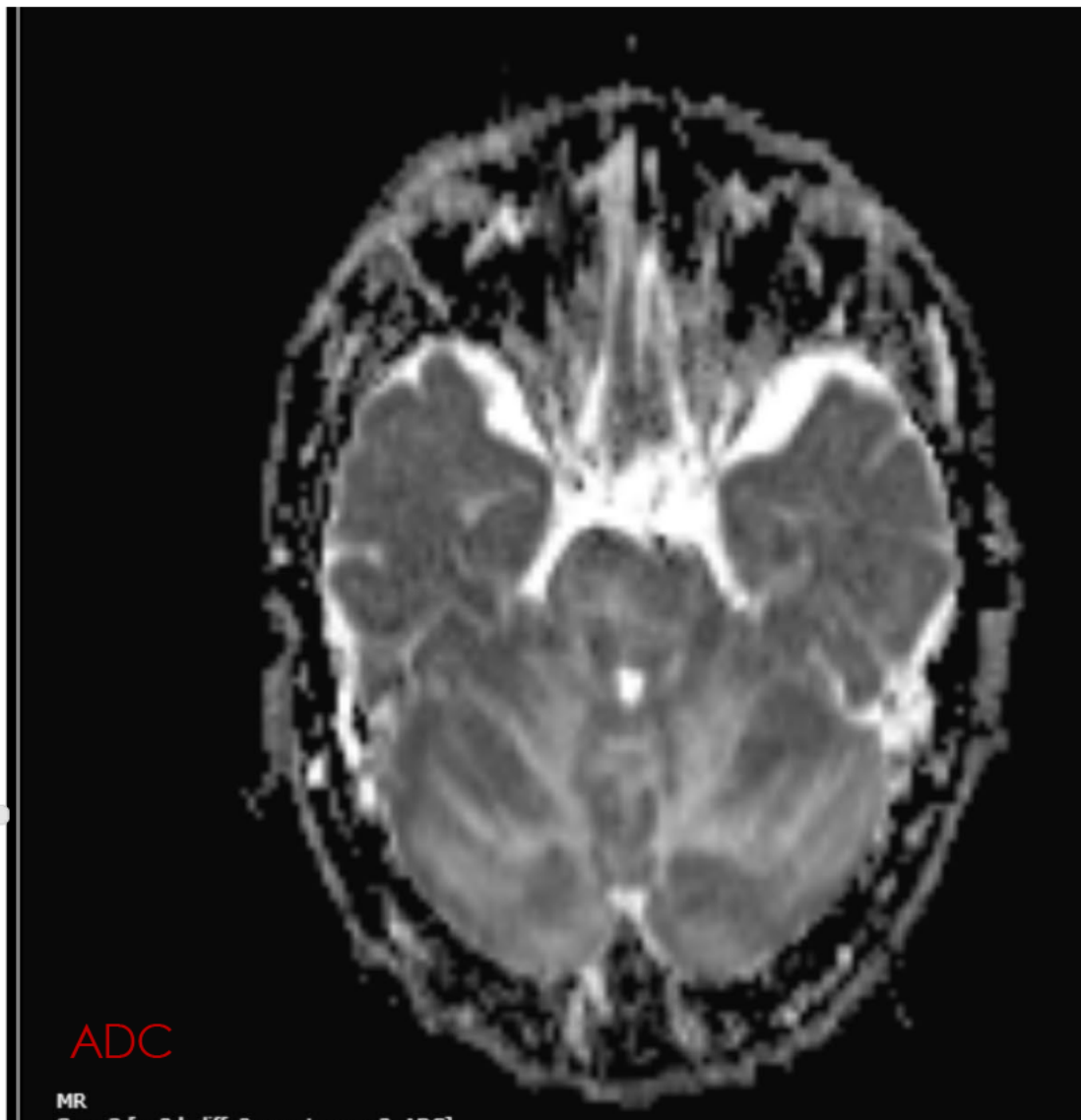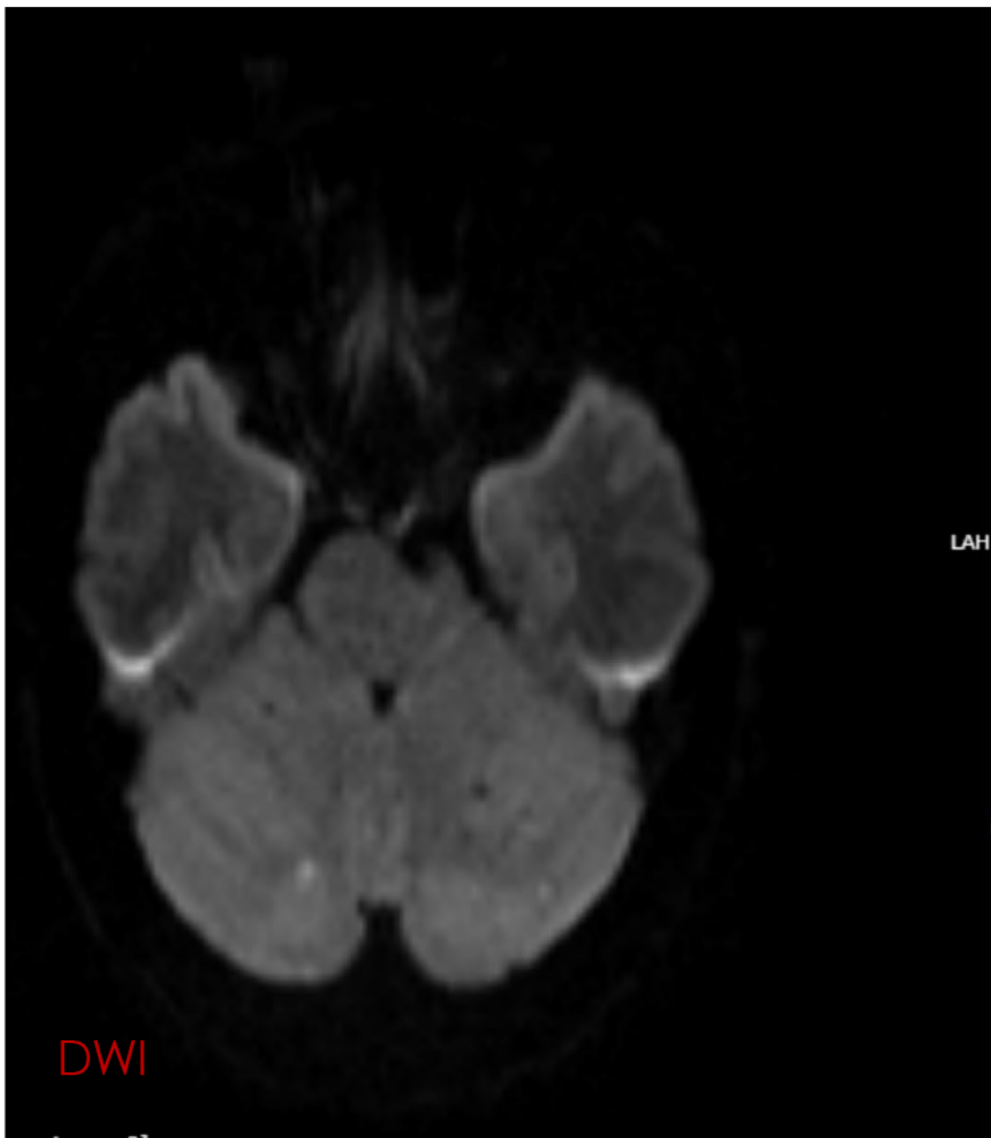
CASE IMAGES

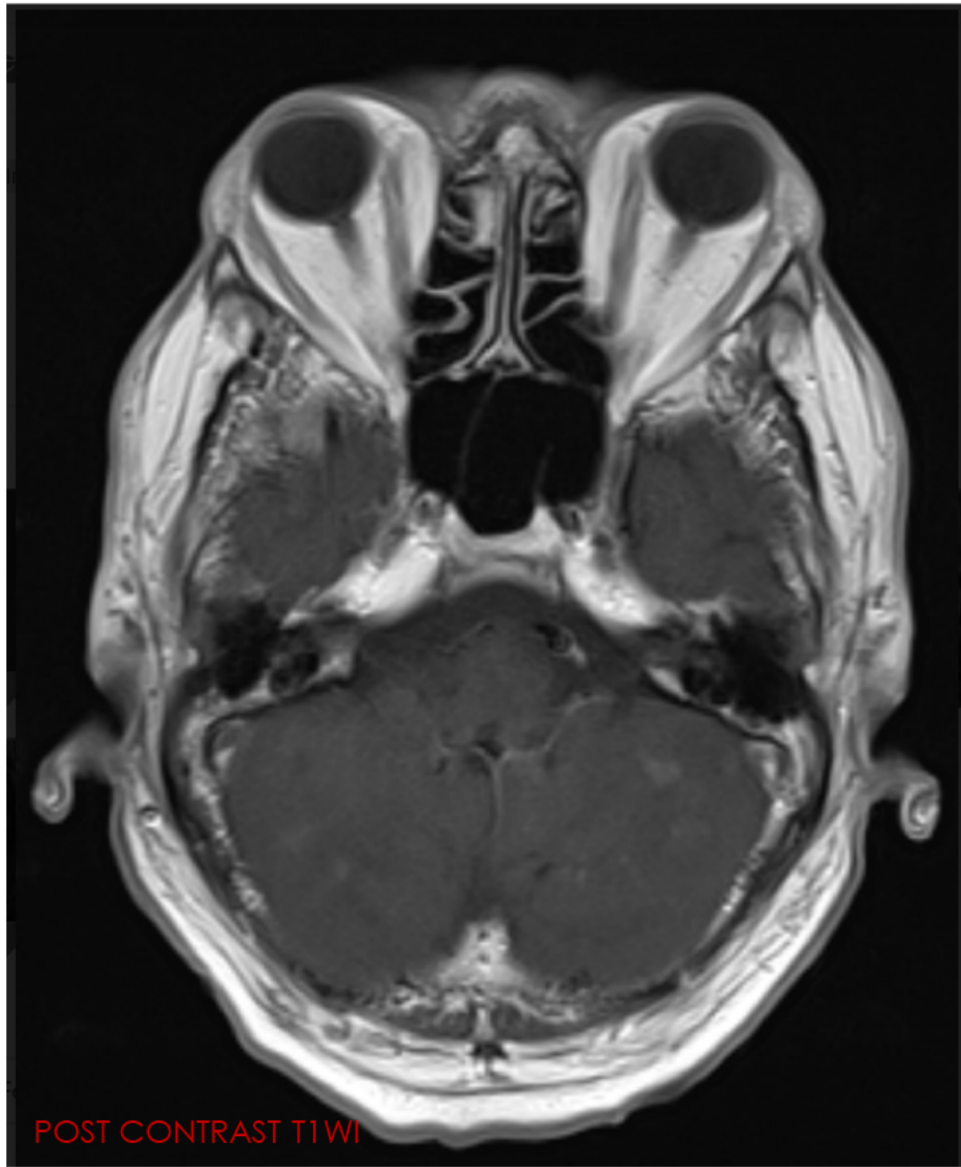
MRI BRAIN











05-2022 14:15:32
05-2022 14:49:36
-94.09 mm
-97.36 mm
16.15 mm

