

## INTRODUCTION

RJ Wruble, MD and Raza Mushtaq, MD - University of Arizona, Tucson, AZ

## CASE IMAGES

## FINDINGS

## DIAGNOSIS

## DISCUSSION

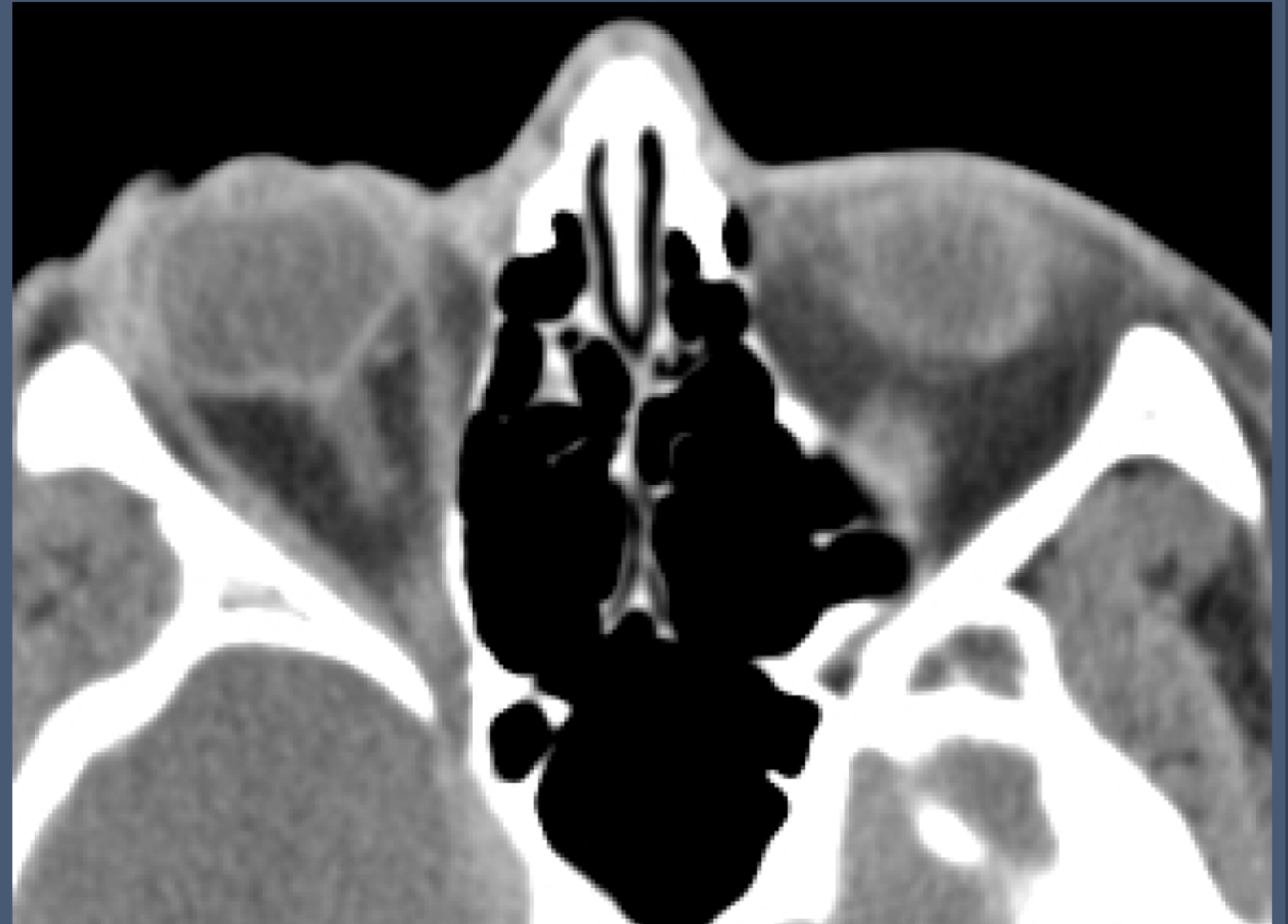## REFERENCES

18-year-old male with a past medical history of:

- Bilateral idiopathic uveitis
- Steroid induced glaucoma

Presented to the emergency department with blurry vision after accidental strike to the face by a car door 2 hours prior

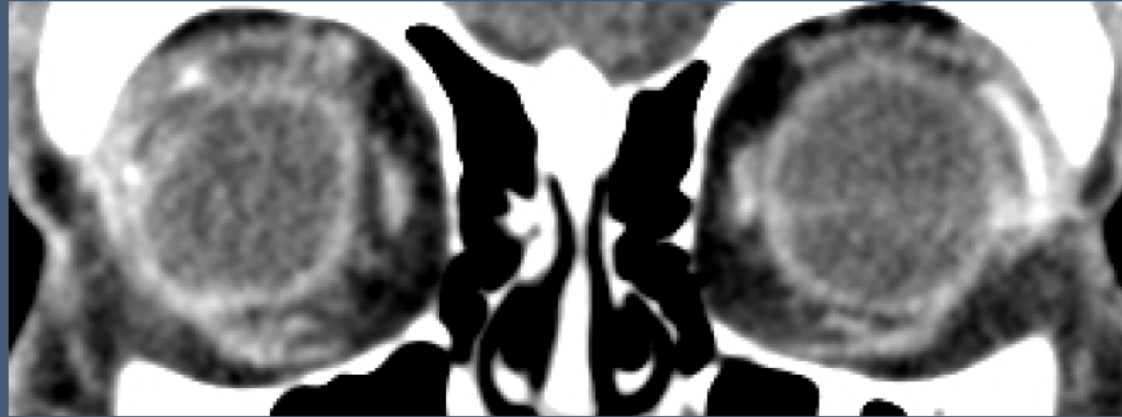
CT Maxillofacial with contrast was ordered by ER



INTRODUCTION

CT Maxillofacial with Contrast

CASE IMAGES



FINDINGS

DIAGNOSIS

DISCUSSION

REFERENCES

