

Case-of-the-Day NON-TRAUMA

Díaz-Canals, Sandra¹; López-Huaman, Jose Luis¹; Canales-Aliaga, Lydia¹

Hospital Universitari Mútua de Terrassa, Terrassa, Spain

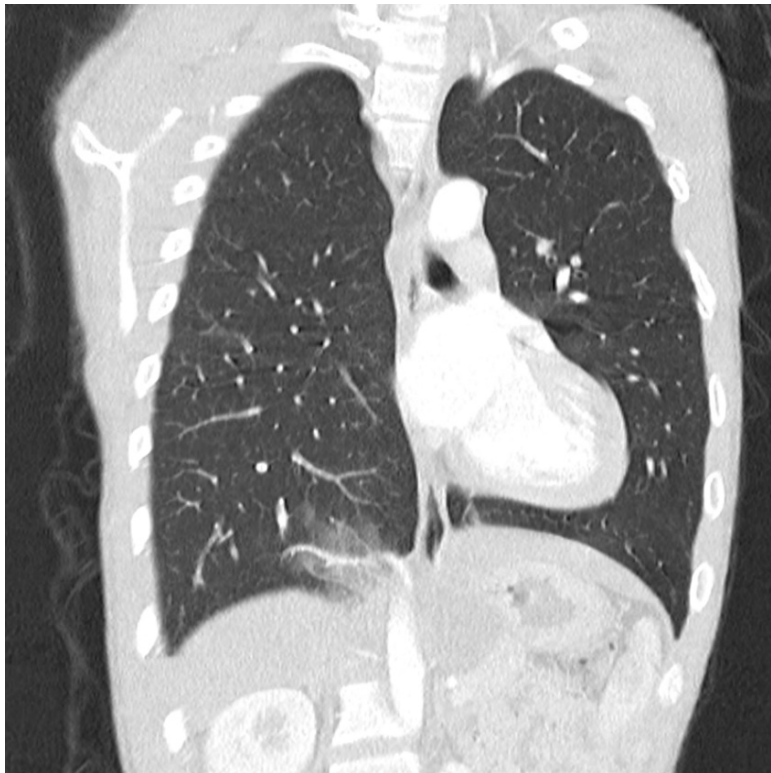


UNIVERSITAT DE
BARCELONA

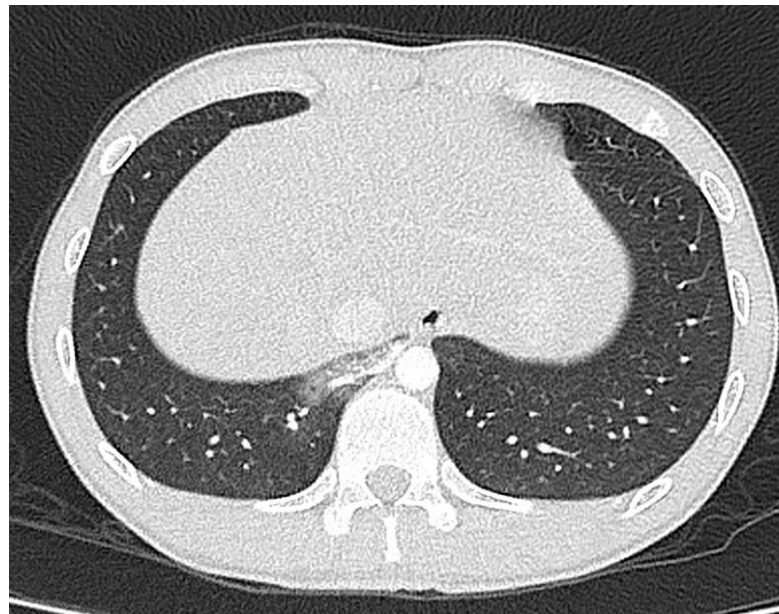


MútuaTerrassa

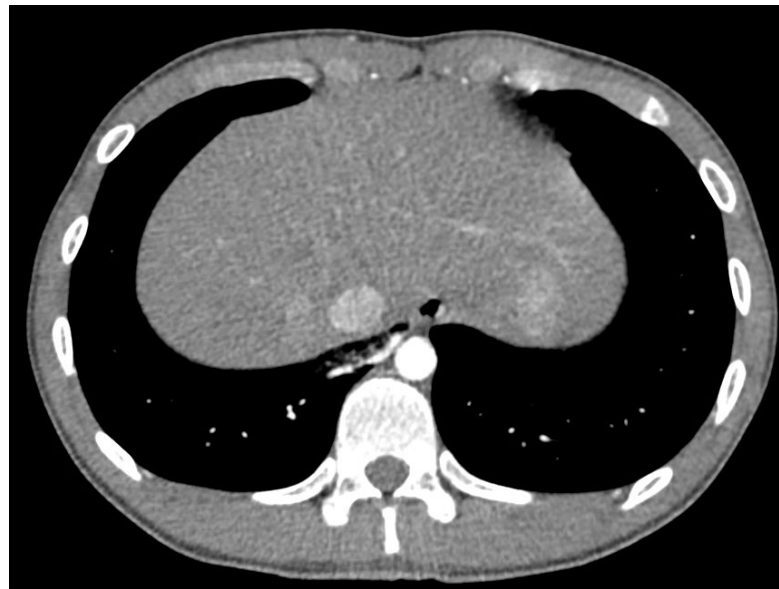Case-of-the-Day NON-TRAUMA Description: An otherwise healthy 19-year-old male presented to our institution with a two-week history of low-volume hemoptysis. On questioning, he admitted to having had a similar episode of hemoptysis a year prior for which he had not sought medical attention. On presentation, Chest X-Ray and laboratory findings were unremarkable.



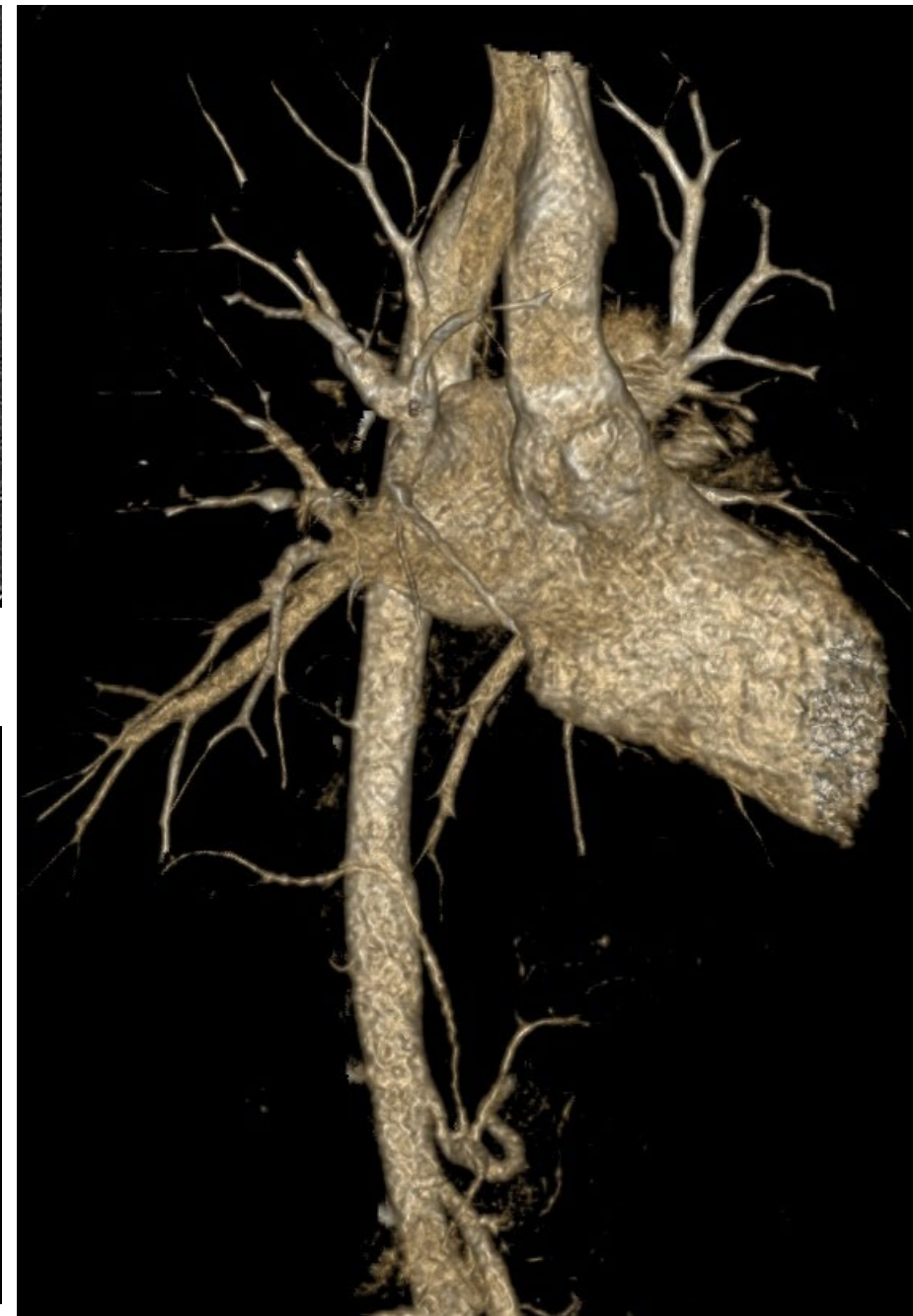CTPA. Coronal MPR with the use of MIP (lung window)



CTPA. Axial MPR with the use of MIP (lung window)



CTPA. Axial MPR with the use of MIP (soft tissue)



CTPA. 3D reconstruction