

ASER 2022 Case of the Day: Non-Trauma

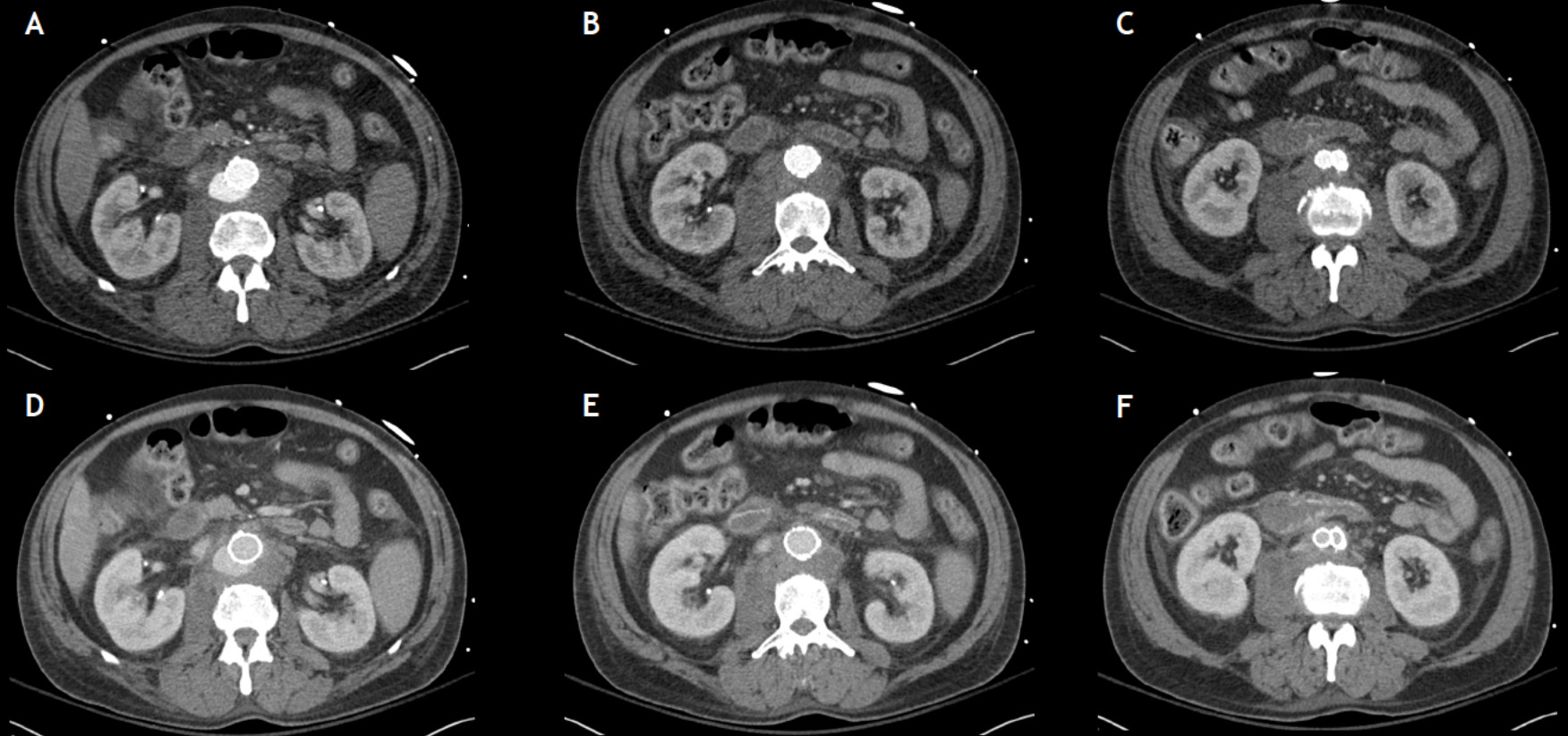


Author: M. Zak Rajput MD

*Mallinckrodt Institute of Radiology,
St. Louis, MO*

History:

- 57-year-old male with back pain, nausea, fever
- Active intravenous drug user
- Endovascular abdominal aortic repair performed 3 months prior



Arterial (A-C) and portal venous (D-F) phase CT images of the abdomen and pelvis with intravenous contrast